

Case Report on Visceral Manipulation in Adolescent Idiopathic Scoliosis

Matias Chahab, Doctor in Osteopathy^{1*}, Pamela Donnet, Osteopath^{2*}, Daniel Hernandez, Physical Therapist^{3*}

¹Private practice, Buenos Aires, Argentina, ²Private practice, Santa Fe, Argentina, ³Faculty of Medicine, University of Buenos Aires, Buenos Aires, Argentina

<https://doi.org/10.3822/ijtm.v15i3.733>

Introduction: Adolescent idiopathic scoliosis (AIS) is a deformity that affects the spine in three dimensions. Even though AIS patients are usually asymptomatic, AIS negatively impacts them, affecting their quality of life and restricting their social life. There are many treatment options but no gold standard. Visceral manipulation (VM) is widely used in osteopathic practice for the treatment of several conditions, but it is little known among the medical community. To the best of our knowledge, there are no scientific studies reporting VM as a treatment alternative for AIS.

Case Presentation: The case was a 14-year-old girl with AIS (baseline Cobb angle of 38.9° in the lumbar spine and 32.3° in the thoracic spine). Although the patient had no physical symptoms, she was recommended for surgery to correct the deformity. The osteopathic assessment indicated that the uterus and pericardium were the main anatomical structures creating tension. Two VM sessions were conducted with a month-and-a-half interval between sessions. The follow-up X-ray revealed a Cobb angle of 32.1° in the lumbar curvature and 34.3° in the thoracic curvature. The results were perceived as an improvement by the patient and her parents. No adverse events or complications were reported.

Discussion: After two sessions of visceral osteopathic treatment, this document reports a 6.8° Cobb angle reduction of the primary curve in a patient with AIS, with the thoracic curvature becoming the major curve.

Key Words: case reports; scoliosis; adolescent; manipulation; osteopathic

INTRODUCTION

Scoliosis is a deformity that affects the spine in the frontal, the sagittal, and the transverse plane. By definition, the curvature of the spine in the frontal plane needs to be of at least 10° (Cobb angle). Depending on onset and severity and if left untreated, scoliosis may alter patients' spinal mechanics and lead to degenerative changes, pain, disability, loss of mobility and function (e.g., cardiac and respiratory dysfunction), even psychological consequences and social life restrictions, that affect patients' quality-of-life.

Adolescent idiopathic scoliosis (AIS) is the most common form of scoliosis. The prevalence of AIS in the population aged 10–16 is 2–4%, and it is more frequent in females. Typically, AIS does not produce physical symptoms. Some curves limit themselves and do not progress, while others develop severe forms (10%). Deformity severity, curvature magnitude, age, function, satisfaction, affected area, and progression potential are some of the factors that specialists take into consideration when deciding in favor or against a surgical approach. Non-surgical interventions include physical therapy with scoliosis-specific exercises and stretching, bracing, and manual treatment.⁽¹⁻³⁾

Even though it is not the gold standard, manual therapy can help improve range of motion (ROM) and ease pain and muscle tension, and it may be a useful approach to treat AIS.⁽³⁾ Osteopathic manual therapy is a holistic, non-invasive approach. Its objective is to strike balance and, therefore, it can be beneficial at multiple levels such as organ function, breathing, bones, circulation, muscles, nerves, and connective tissue. Visceral manipulation (VM) has been

a part of osteopathic clinical practice for many years, and has been used in many conditions such as nonspecific neck pain, lower-back pain, constipation, and dyspepsia.⁽⁴⁻⁶⁾

Few papers about the treatment of idiopathic scoliosis report the efficacy of manual therapy and osteopathy.⁽⁷⁾ We have not found any scientific publications reporting VM in AIS.

CASE PRESENTATION

The patient was a 14-year-old Caucasian female attending secondary school. She was born by unplanned Caesarian section. She had no relevant diseases or surgeries and there was no history of scoliosis in her family. When the patient was 13 years and 6 months old (post-menarche), she was diagnosed with AIS by an orthopedic spine specialist. She underwent chiropractic treatment and Global Postural Reeducation (GPR) sessions, but no improvement was perceived. When the patient visited the orthopedist for a checkup, the X-ray (see Figure 1A) showed a left lumbar curve with a Cobb angle of 38.9° and a right thoracic curve of 32.3°. She was recommended surgery, but she and her parents rejected the idea.

The patient never reported back pain. As she continued growing up, the progression of the curvature implied health risks, so they decided to try a different treatment option with osteopathy (see Figure 2). MC assessed and treated her at the first session, an osteopath with a 10-year experience, certificated in VM from the Barral Institute (www.barralinstitute.com), and the second session was conducted by PD, an osteopath with a six-year experience, trained in VM at the Barral Institute (both authors of this study). The patient was assessed while standing up, sitting, and lying prone and supine on the treatment couch, and received the osteopathic treatment in the osteopath's private office in Santa Fe, Argentina (see Table 1).

The VM was performed indirectly by mobilizing the organ through contact with more superficial structures (see Table 2), while the osteoarticular intervention was performed directly by palpating the structure to be treated. Indirect techniques (i.e., near the compromised tissue, injury, or restriction) and/or direct

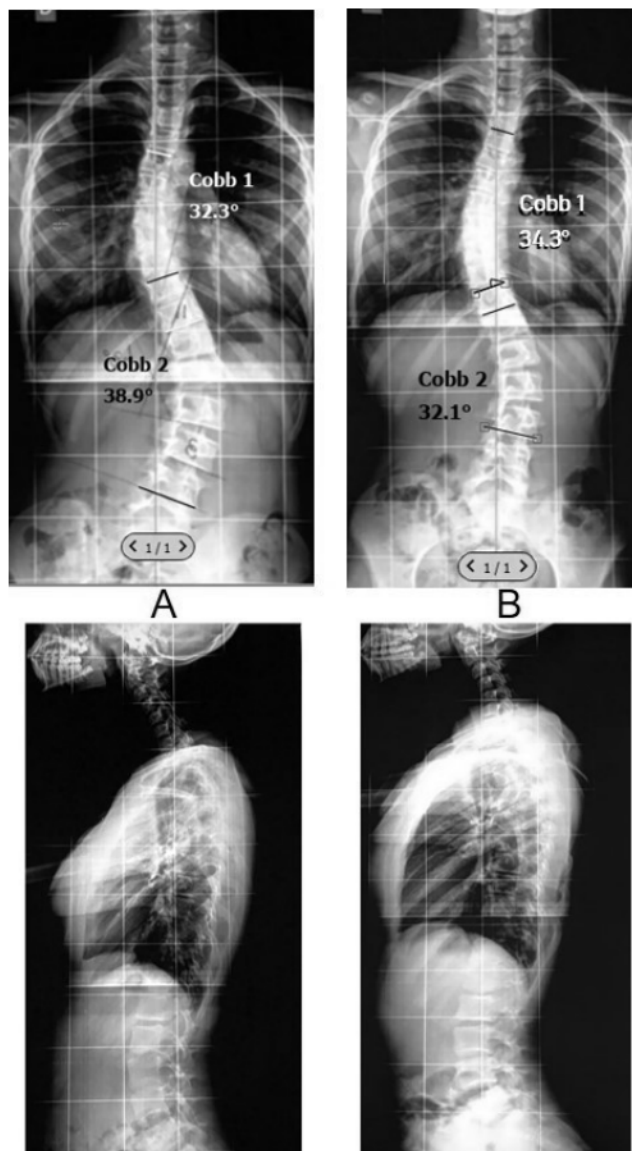


FIGURE 1. Spinograms: (A) anteroposterior and lateral scoliosis series, before treatment; (B) anteroposterior and lateral scoliosis series, after two osteopathic sessions.

techniques (i.e., away from compromised tissue, injury, or restriction) were used as appropriate. The movement of tissues perceived with the hands was followed along while a light force was applied in the direction of the tissue intended to move until release was achieved. When this happened, tension or movement was no longer felt, the tissue quality improved, and mobility was regained. The techniques lasted no longer than 40 sec to avoid irritation of the vascular and neural systems. Each session was less than 50 min long.

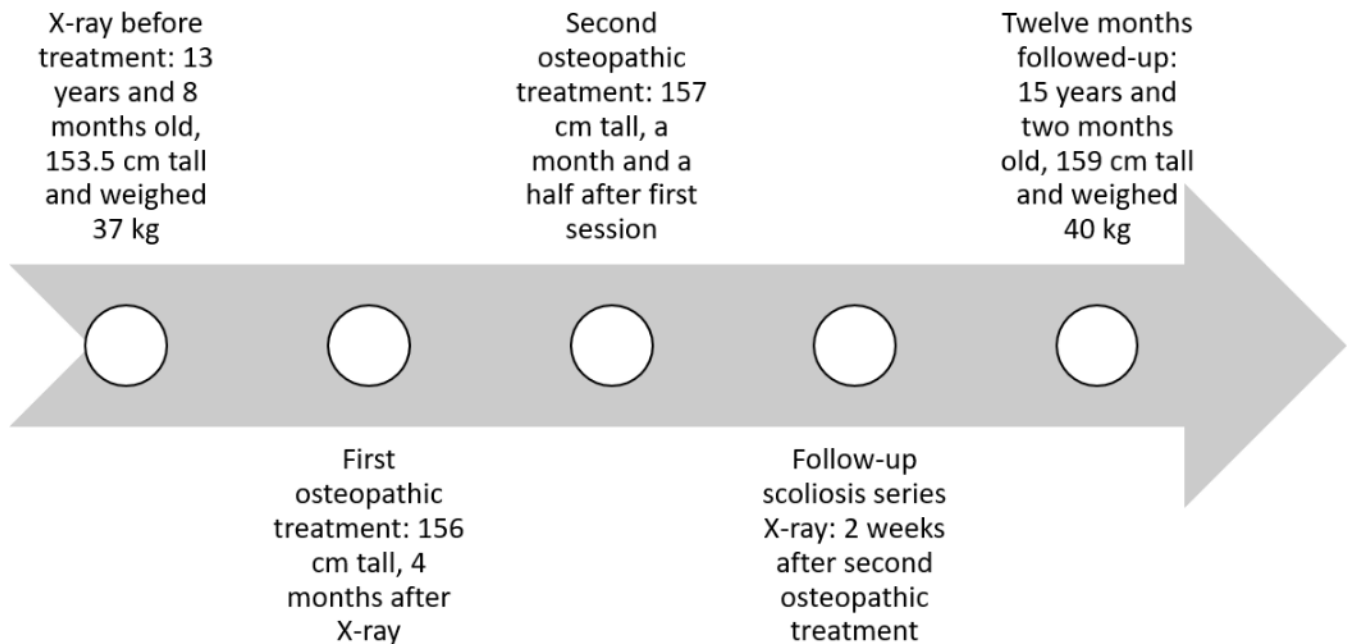


FIGURE 2. Timeline.

RESULTS & FOLLOW-UP

Changes detected by the osteopath after treatment are reported in the re-evaluation item of Table 1. The patient grew 1 cm in height between sessions, and she reported feeling “more locked up before the first two sessions and released after them”. She added: “[I] can do more things, breathe better, and move better”.

Two weeks after the second osteopathic session, a follow-up scoliosis series X-ray was taken (see Figure 1B). Measurements revealed a 32.1° Cobb angle in the lumbar curvature and 34.3° in the thoracic curvature, and less dorsal kyphosis and head antepulsion were observed.

The patient was followed up for 12 months after the two osteopathic sessions (see Figure 3), and followed the recommendations as indicated by the osteopath.

The patient presented no adverse events or complications during or after the osteopathic sessions.

DISCUSSION

Most AIS patients experience disease progression during growth. Treatment options include physical therapy with exercises and stretching for non-severe curves, brace wearing 20 hours a day for progressive curves or > 25°–30° curves before bone

growth completion (which occurs at the age of 18 for boys and 16 for girls, in most cases), and surgery in curvatures exceeding 40° or 50°.

Exercises may help AIS patients improve spinal deformity measures, but the evidence is of very low quality. A number of studies demonstrated that bracing may have a positive impact on AIS, but wearing a brace is quite uncomfortable and may cause skin irritation, limited movement, chest wall deformation, and poor self-esteem and body image. This leads to non-compliance and, thus, bracing remains controversial. As a result, many patients shift from traditional treatments to holistic approaches like osteopathy. However, manual therapy and osteopathy are not supported by adequate scientific evidence. For the treatment of AIS, no clear conclusions can be drawn due to poor methodological quality or lack of studies.^(1-3,7-10)

This study has been performed according to the Code of Ethics of the World Medical Association (Declaration of Helsinki) for experiments involving humans. Recommended publications about writing case reports were consulted to prepare our report.⁽¹¹⁻¹⁴⁾ The patient and her parents consented to the publication of this case report.

The reported case study refers to an AIS patient aged 14 presenting a double curve pattern, a 38.9° Cobb angle lumbar curve

TABLE 1. Evaluation and Treatment of the Two Osteopathic Sessions

<i>Variable</i>	<i>First Osteopathic Session</i>	<i>Second Osteopathic Session</i>
Initial Examination	Asymmetry of the lower limbs (shorter left leg) and scapulae, forward head posture, a positive result in Adam's forward bend test, a spine curvature with thoracic concavity to the left and lumbar concavity to the right, limited rightward rotation of the head and limited right hip flexion with the knee extended.	Left shoulder was lower and anteriorly rotated compared to the right shoulder. Right pelvis was higher and posteriorly tilted. Right leg was externally rotated, feet were flat. Cervical rectification and increased thoracic kyphosis following a positive Adam's forward bend test. Full-range neck, spine and limb mobility and a normal gait.
Main Problem Detected	Tension in the uterus.	Pericardial tension and rigidity at thoracic level.
Techniques Applied	Release of the uterosacral and right broad ligaments, uterine artery, and aponeurosis of the sacrum, rectum, uterus, bladder, and pubic area. The sacroiliac, sacrospinous, and sacrotuberous ligaments, obturator membrane on both sides, lower peritoneum, and sigmoid colon near the rectum were treated.	Release of the sternocostal joints, radiate ligaments of the head of rib on both sides, transverse muscle of thorax, pretracheal fascia, left pulmonary fissure, upper and lower sterno-pericardial ligament, vertebro-pericardial ligament, and pericardium were treated.
Patient Position	Lying comfortably in supine position or on her side depending on the structure to be treated and the technique to be used. Parts of her body were conveniently placed for better contact and mobilization of the structure to be treated.	
Practitioner Position	Depending on the technique, was either standing or sitting on the side of the patient as required for better manual contact, or behind the patient's head.	
Repetition of Techniques	Techniques were repeated once, twice or three times as needed and the length varied depending on tissue status, viscoelasticity, and response to tension release inputs.	
Re-evaluation	Improvement in spine and shoulder mobility, increased cervical rotation and lateral bending ROM and restored symmetry of the lower limbs. Tension in uterus was no longer perceived. However, tension was detected in the pericardium.	Tension in the pericardium and thorax was no longer perceived. In addition, improved thoracic elasticity was observed, and scapulae and pelvis were less asymmetric compared to the initial assessment.
Recommendations After Treatment	To suspend any physical activity involving jogging, running or skipping, and adopt healthier dietary habits. To return to the second session in a month's time.	To increase fruit and vegetable intake (which was quite low), get a new X-ray in the next few days, start some physical activity, and return in three weeks for a follow-up session.

with leftward convexity, and a 32.3° Cobb angle thoracic curve with rightward convexity, which matches the most common patterns of AIS.⁽²⁾ Although the patient had no physical symptoms, she was recommended surgery to correct her deformity. The patient was treated with two VM sessions following the teachings of the Barral Institute with an interval of a month and a half. VM is a manual therapy that relies on harmless soft interventions to stimulate normal mobility, tone, and motion of visceral and connective tissue attachments. Through palpation and mobility test on the anatomical structure, VM therapists

can locate tissue restrictions or areas of greater tension, and use their hands to mobilize the affected tissues to stimulate self-regulation mechanisms, release tissue, and restore form and function.⁽⁴⁾ A scoliosis series X-ray taken two months after the first osteopathic intervention and two weeks after the second osteopathic session showed a lumbar Cobb angle of 32.1° and a thoracic Cobb angle of 34.3°. The X-rays were taken in the same diagnostics center under the same instructions and at the same time of day. The Cobb angles in both X-rays were measured by an orthopedic spine specialist using the

digital computer software Surgimap Spine (Surgimap, Methuen, MA). Digital Cobb angle measurement and definition of the terminal vertebrae have shown excellent intra- and inter-observer reliability, with

TABLE 2. Visceral Manipulation of the Two Osteopathic Sessions

Variable	Visceral Manipulation of the Uterus	Visceral Manipulation of the Pericardium
Patient Position	Lying supine with hips and knees flexed, feet flat on the surface.	Lying supine on the treatment couch with legs extended.
Practitioner Position	Standing on the right side of the patient.	Standing behind the head section.
Manual Contact	Hands on the uterus with the thumbs on the right side, index and middle fingers on the left side, at a distance of 2 fingerbreadths from the pubic ramus. The practitioner placed applied pressure until the uterus was perceived.	Hands overlapped (dominant on top) at a 45° angle towards the left on the angle of Louis up to the fifth left rib in the midclavicular line. The practitioner placed applied pressure until the pericardium was perceived.

1° variability in measured Cobb angle for experienced observers.⁽¹⁵⁾ The patient grew 2.5 cm in height since the X-ray before treatment and her first osteopathic session. Therefore, the Cobb angle difference may have been different from the perceived 6.8° reduction of the primary curvature (lumbar) and the 2° increase in the thoracic curvature. According to the Scoliosis Research Society recommendations, Cobb angle is a primary outcome. A curve progression of ≤ 5° in the Cobb angle, after reaching skeletal maturity, is commonly used to define the success of conservative treatments.⁽¹⁶⁾ This case report documents a reduction of over 6° in the lumbar curvature and an increase of 2° in the thoracic curvature. As a result, the thoracic curvature became the major curve, per the last radiographic follow-up—a very unusual situation.

The patient and her parents reported improvements since the beginning of the osteopathic treatment and are now undergoing a conservative treatment with medical follow-up. The patient’s compliance with the osteopathic treatment was good. She attended all the appointments as indicated. The second session was postponed by two weeks due to local COVID-19 pandemic restrictions imposed in Argentina that prohibited practice until official authorization was given.

Scoliosis is usually described on the side of the convexity. According to the teachings of the Barral Institute, the concavity is usually referred to as “the body embraces

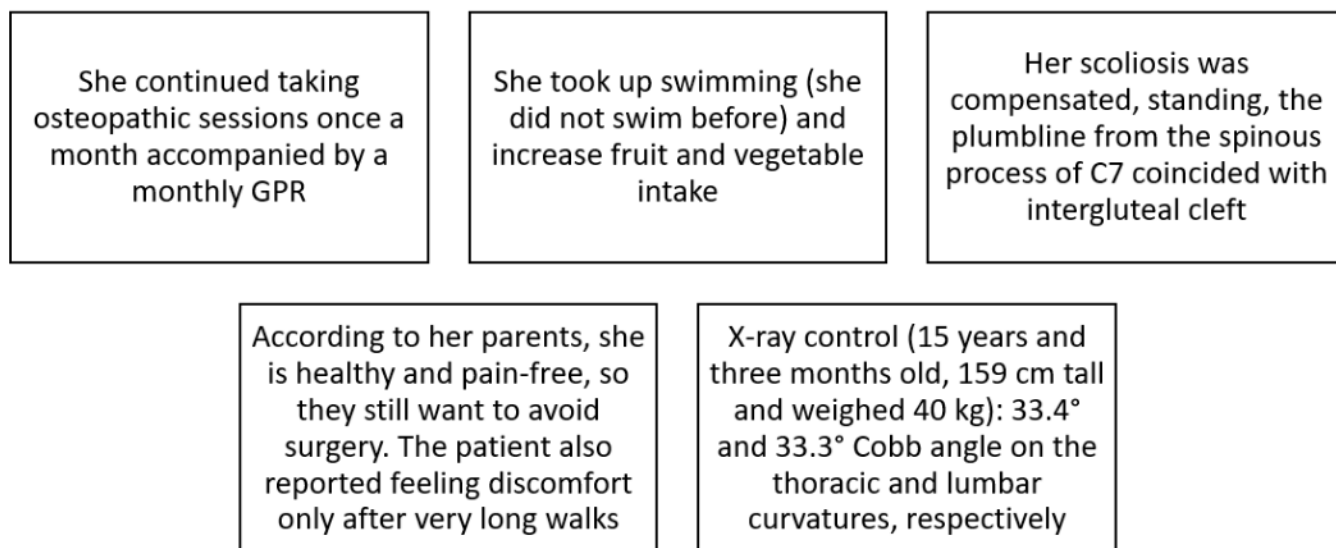


FIGURE 3. Twelve-month follow-up.

the injury, based on the principle that the anatomical structures on that side generally present more tension to be released.⁽⁴⁾ In clinical terms, this case is a scoliosis with a right lumbar concave curve for which the uterus and related structures were treated, and a left concave thoracic curve where the pericardium and related structures were treated.

An identifiable weakness of this study, besides being a descriptive and retrospective study, is the fact that the patient was treated by two different practitioners. The more experienced practitioner was unable to treat the patient in the second session since he was abroad for a long time. However, he was able to supervise the treatment remotely. There were no X-rays immediately before starting osteopathic treatment, only the patient and family's perspective of no improvement, so the actual Cobb angles at that time are not precisely known. Another limitation was that no objective assessment tools, such as goniometers or inclinometers, were utilized to evaluate joint mobility, and no validated questionnaires were used. Detailed descriptions of the techniques were not provided since individuals have unique ways to compensate and the therapist must adapt to the patient's characteristics and situation, and body tissues respond in various ways to achieve release and self-healing. Our results cannot be extrapolated or applied to other AIS patients.

There is poor scientific evidence regarding VM in AIS. More studies are needed to justify its use. This case report documents a 6.8° Cobb angle reduction in the primary curve following a visceral osteopathic treatment in a patient with AIS after two sessions.

ACKNOWLEDGMENTS

The authors would like to thank Doctor José Baigorria for his assistance in the interpretation of images, and the patient and her parents for their collaboration.

CONFLICT OF INTEREST NOTIFICATION

This study did not receive any specific grant from funding agencies in the public, commercial, or not-for-profit sectors. Matias Chahab is an instructor for the Barral

Institute. The other authors declare no conflicts of interest.

COPYRIGHT

Published under the [Creative Commons Attribution-NonCommercial-NoDerivs 3.0 License](https://creativecommons.org/licenses/by-nc-nd/3.0/).

REFERENCES

1. Bettany-Saltikov J, Weiss HR, Chockalingam N, Taranu R, Srinivas S, Hogg J, et al. Surgical versus non-surgical interventions in people with adolescent idiopathic scoliosis. *Cochrane Database Syst Rev*. 2015;(4):CD010663.
2. Comité Nacional de Adolescencia SAP; Comité de Diagnóstico por Imágenes SAP; Sociedad Argentina de Ortopedia y Traumatología Infantil; Sociedad Argentina de Patología de la Columna Vertebral (SAPCV). Consenso de escoliosis idiopática del adolescente [Adolescent idiopathic scoliosis]. *Arch Argent Pediatr*. 2016;114(6):585–594.
3. Lotan S, Kalichman L. Manual therapy treatment for adolescent idiopathic scoliosis. *J Bodywk Mov Ther*. 2019;23(1):189–193.
4. Barral JP, Mercier P. *Visceral Manipulation*. Eastland Press: Seattle, 2005.
5. Silva ACO, Oliveira CS, Biasotto-Gonzalez DA, Fumagalli MA, Politti F. Visceral manipulation decreases pain, increases cervical mobility and electromyographic activity of the upper trapezius muscle in non-specific neck pain subjects with functional dyspepsia: two case reports. *Int J Ther Massage Bodywork*. 2019;12(2):25–30.
6. Zollars JA, Armstrong M, Whisler S, Williamson S. Visceral and neural manipulation in children with cerebral palsy and chronic constipation: five case reports. *Explore*. 2019;15(1):47–54.
7. Czaprowski D. Manual therapy in the treatment of idiopathic scoliosis. Analysis of current knowledge. *Ortop Traumatol Rehabil*. 2016;18(5):409–424.
8. Płaszewski M, Bettany-Saltikov J. Non-surgical interventions for adolescents with idiopathic scoliosis: an overview of systematic reviews. *PLoS One*. 2014;9(10):e110254.
9. Zhang Y, Li X. Treatment of bracing for adolescent idiopathic scoliosis patients: a meta-analysis. *Eur Spine J*. 2019;28(9):2012–2019.
10. Zhou Z, Liu F, Li R, Chen X. The effects of exercise therapy on adolescent idiopathic scoliosis: an overview of systematic reviews and meta-analyses. *Complement Ther Med*. 2021;58:102697.
11. Gagnier JJ, Kienle G, Altman DG, Moher D, Sox H, Riley D. The CARE guidelines: consensus-based clinical case reporting guideline development. *Glob Adv Health Med*. 2013;2(5):38–43.

12. Hoffmann TC, Glasziou PP, Boutron I, Milne R, Perera R, Moher D, et al. Better reporting of interventions: template for intervention description and replication (TIDieR) checklist and guide. *BMJ*. 2014;348:g1687.
13. Riley DS, Barber MS, Kienle GS, Aronson JK, von Schoen-Angerer T, Tugwell P, et al. CARE guidelines for case reports: explanation and elaboration document. *J Clin Epidemiol*. 2017;89:218–235.
14. Munk N, Boulanger K. Adaptation of the CARE guidelines for therapeutic massage and bodywork publications: efforts to improve the impact of case reports. *Int J Ther Massage Bodywk*. 2014;7(3):32–40.
15. Prestigiacomo FG, Hulsbosch MHHM, Bruls VEJ, Nieuwenhuis JJ. Intra- and inter-observer reliability of Cobb angle measurements in patients with adolescent idiopathic scoliosis. *Spine Deform*. 2022;10(1):79–86.
16. Schreiber S, Parent EC, Hill DL, Hedden DM, Moreau MJ, Southon SC. Patients with adolescent idiopathic scoliosis perceive positive improvements regardless of change in the Cobb angle—Results from a randomized controlled trial comparing a 6-month Schroth intervention added to standard care and standard care alone. SOSORT 2018 Award winner. *BMC Musculoskelet Disord*. 2019;20(1):319.

Corresponding author: Matias Chahab, Doctor in Osteopathy, Maldonado 50 1A, Zip Code 28006 Madrid, Spain
E-mail: matiaschahab@hotmail.com